

---

# The Canadian Collar: A New Cervical Spine Orthosis

(adjustable, cervical, collar, modular, occupational therapy, orthosis, tubular)

---

Richard E. Hannah

Sylvia D. Cottrill

---

*We developed a cervical collar (the Canadian collar) in response to the requirements of occupational therapists who manage arthritis patients. This orthosis overcomes the problems of heat and inadequate support common to many soft collars. The collar is constructed from nylon and polyvinyl chloride tubing, clipped together by nylon junctions, and from chin and breastplate supports of molded nylon rod. Preliminary clinical trials have been conducted on 20 patients, 15 of whom had arthritis. An additional 60 patients with various disabilities have been fitted. The collar has been readily accepted by patients, therapists, orthotists, and physicians.*

Occupational therapists at the Arthritis Centre in Vancouver, BC expressed a need for a cervical collar that could manage cervical spine symptoms associated with rheumatoid arthritis (RA) and osteo-arthritis (OA).

Typically, prefabricated foam or custom-made plastazote collars are used to protect against traumatic atlanto-axial subluxation, to relieve pain and neurological symptoms, and to enhance function through positioning. However, occupational therapists at the Arthritis Centre said that the major failings of these soft foam or plastazote collars are that they lack firm resistance against flexion and they retain heat. Subjective findings regarding positioning have been supported by radiological evaluations of various cervical orthoses (1). Other factors, such as cosmesis, light weight, ease of adjustment, and reasonable cost, were also cited as important for arthritis patients; none of the existing collars met all of the above requirements. Existing cervical orthoses have been classified as soft, poster, cervico-thoracic, and halo-skeletal fixation (2); the more rigid types demonstrated good support (3). However, functional, cosmetic, and cost restraints usually preclude the use of the more rigid types to manage arthritis.

Thus, a new orthosis was needed that could be fabricated and fitted by occupational therapists and which gave more support than existing collars. This new collar should not only provide good support against flexion of the cervical spine but also be comfortable, cool, and easy to fit.

A new family of orthoses, Tubular Orthoses (4), is under development by the Medical Engineering Resource Unit at the University of British Columbia. These orthoses having tubing and clip-together components are usually cooler, lighter, and more adjustable than most orthoses and provide good support without inhibiting function. We used this approach to design and construct the Canadian Collar.

## Collar Design

The basic structure of the Canadian Collar is as follows: two pieces of pliable, clear polyvinyl chloride (pvc) tubing, which form the upper and lower perimeters of

*Richard E. Hannah, MSc, and Sylvia D. Cottrill, OTR, are part of an orthotics research team, Medical Engineering Resource Unit, The University of British Columbia, % Shaughnessy Hospital, Vancouver, BC V6H 3N1, Canada.*

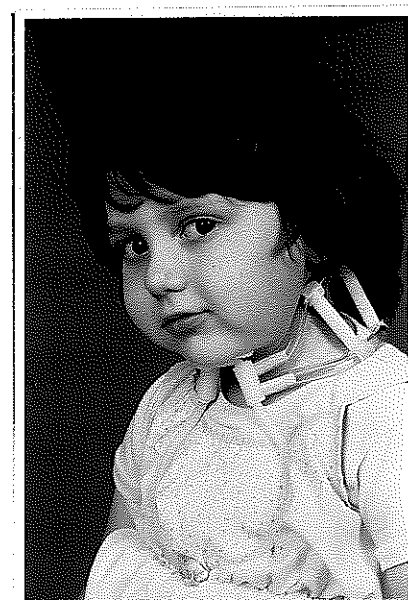
the collar, and six short, rigid nylon tubes, which provide vertical support (see Figure 1). A specially designed part, a T-junction, connects the pvc tubing to the short nylon tubes by forming a right angle union between two tubes (see Figure 2). A preformed nylon rod chin, breastplate pieces, and small chin cup provide anterior support.

Custom fitting is achieved by cutting the pvc tubing to length and selecting nylon tubes of appropriate length. Three pairs of nylon tubes are used. They are symmetrically arranged anteriorly, laterally, and posteriorly and are selected from seven pairs of tubes ranging in length from 37 mm (1.5 in.) to 100 mm (4 in.) in 12-mm (.5-in.) increments. This facilitates rapid assembly and adjustment of the orthosis and eliminates the need to cut the nylon tubes.

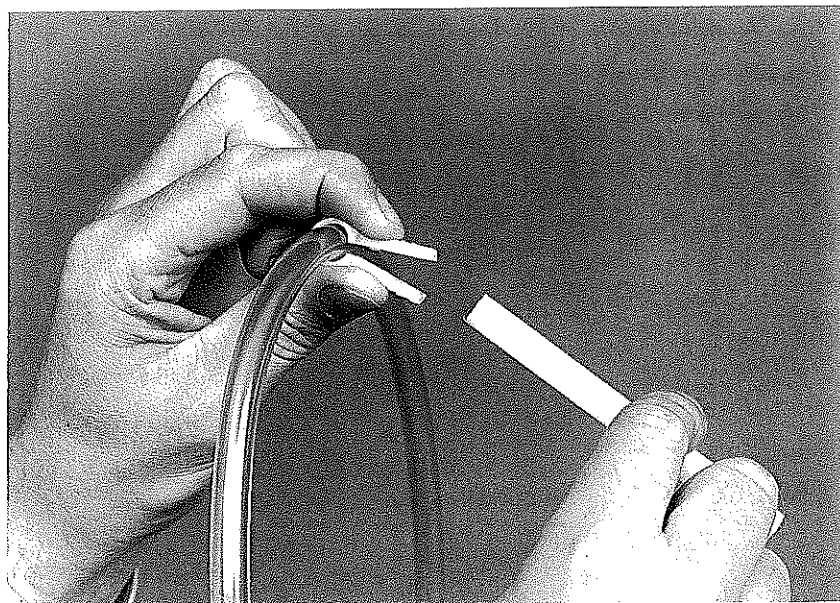
### Collar Assembly

The assembly process starts by placing the components on a work

**Figure 1**  
A patient with juvenile rheumatoid arthritis



**Figure 2**  
Plugging in the T-junctions



surface. Two posterior nylon support tubes are selected. These normally run from about C<sub>7</sub> to the occiput, but longer or shorter tubes can be selected to avoid tender areas. The posterior tubes are clipped between the upper and lower pvc tubing using T-junctions. Nylon tubes for lateral support are selected and clipped in place. Their lengths are about half the distance between the clavicle to the angle of the mandible (see Figure 3). The pvc tubing is trimmed to leave a 50-mm (2-in.) gap anteriorly, and T-junctions are inserted into the ends.

Two short anterior nylon tubes are selected to provide the desired position of flexion. These anterior tubes are inserted into the T-junctions in the ends of the pvc tubing. The nylon rods of the chin support and the breastplate are inserted into the anterior support tubes. These also provide the means of securing and removing the collar

(see Figure 4). Assembly and fitting of the collar takes 30 to 45 minutes.

### Preliminary Clinical Trial

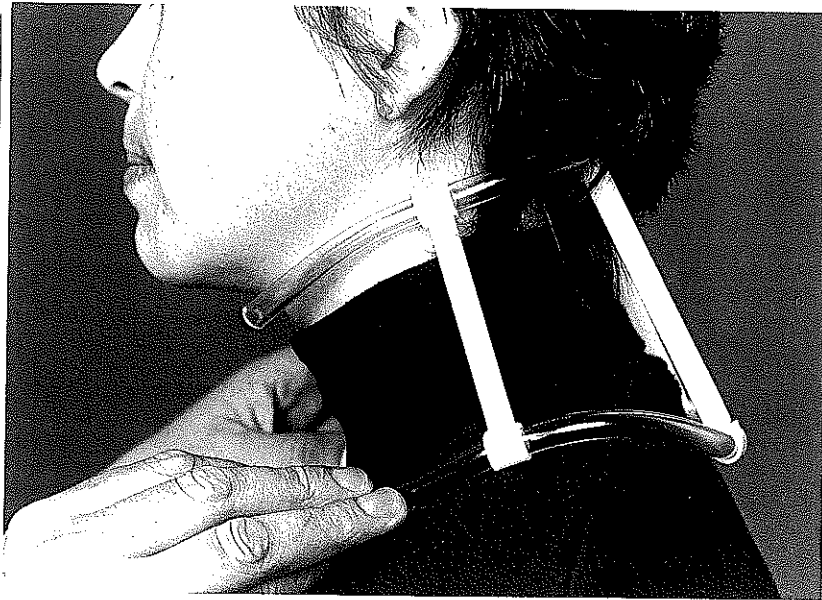
#### *Objective*

The objective of the preliminary clinical trial was to determine whether this new collar would meet the requirements of the patient (comfort and cosmesis), the therapist, and the physician (support, positioning, rapid fabrication, and availability).

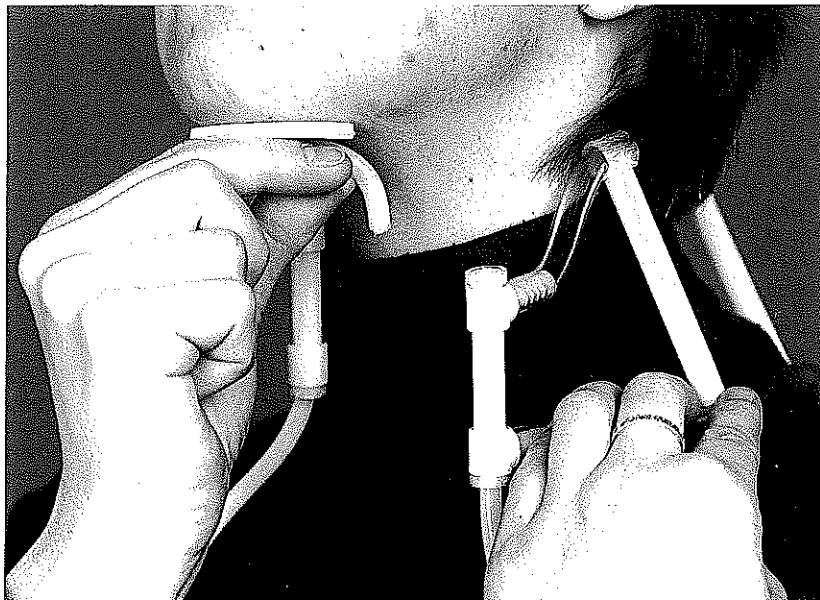
#### *Patient Population*

Fifteen orthoses were prescribed and fitted in the first three months of trial, primarily to elderly, arthritic patients. However, one child with juvenile rheumatoid arthritis (JRA) was fitted. An additional five collars were fitted to patients with the following disabilities: cerebrovascular accident (CVA), amyotrophic lateral sclerosis (ALS), os-

**Figure 3**  
Checking for lateral fit



**Figure 4**  
Securing the orthosis



teomyelitis, whiplash injury, and spinal cord injury (SCI). A breakdown of the patients by diagnosis, age, and sex is given in Table 1. The mean age of the patients was

53 years (range 4.5–79 yrs); 13 were female and 7 were male.

#### *Evaluation*

The patients were contacted by

telephone 10 to 21 weeks after the orthoses were fitted. Each patient was asked to discuss how often he or she used the orthosis, give its functional or comfort-related problems, and compare the new orthosis with any previous collar used. The patients' responses are given in Table 1, along with a classification of the successes or failures of the orthoses. The orthosis was classified as a success if it a) was used on a regular basis or for specific tasks, b) relieved a patient's pain, and c) improved a patient's cervical stability.

#### **Results**

The success-failure rate was as follows: 15 patients were considered successful, 3 were partial successes, and 2 were failures. The first patient fitted was classified as a failure. This patient was refitted after 16 weeks, but she still said the collar was uncomfortable, too restricting, and offered no pain relief. However, her disability was not clearly diagnosed, and this may have contributed to the failure. The other failure patient offered similar reasons (*patient 20*) of dissatisfaction.

Partial successes patients (*patients 12, 14, 18*) had compound problems and/or poor motivation: *patient 12* had severe rheumatoid arthritis (RA) that frequently confined her to bed, *patient 14* was in the later stages of ALS and died within ten weeks of being fitted with the collar, *patient 18* did not fully appreciate the importance of head support, even though he lost consciousness on two occasions because of atlanto-axial subluxation.

#### *Patient Comments*

Patients considered a success cited that the collar gave coolness and good support, unlike foam or

cause the new collar was thought to be too restrictive for this activity (*patient 10*). However, patients as passengers in cars (*patients 5, 6, 9, 15*) found support and pain relief from the collar when traveling.

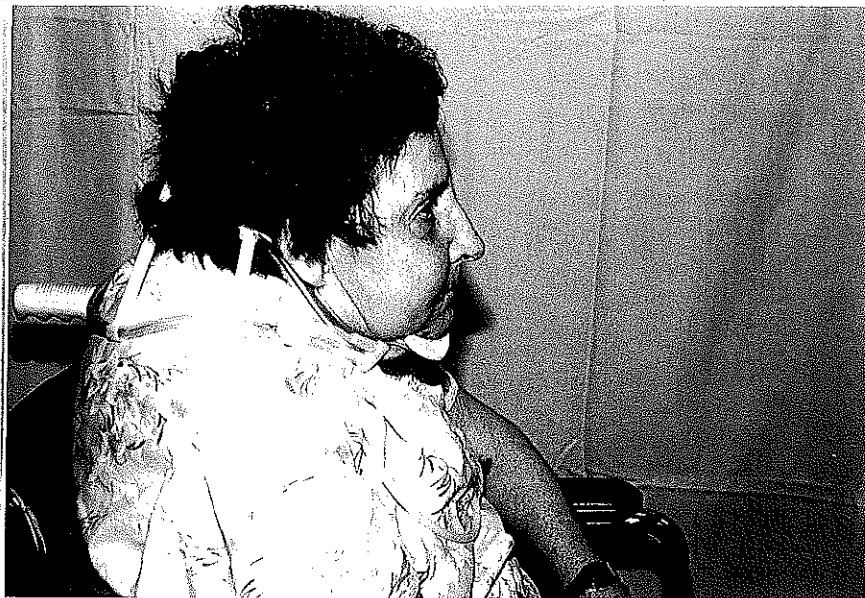Daily use of the collar varied from occasional use for specific tasks (*patient 9*) to almost continuous use during waking hours (*patient 2*). *Patient 2* had a spinal cord injury at C<sub>6</sub>, which was diagnosed as either a chipped facet or a slipped disc; this injury was the result of a skiing accident. He had a slight loss of sensation in his right thumb. He was fitted while he was supine and wore the collar continuously for five weeks during awake hours, except for occasional periods when he sat in a high-backed chair. His only complaints were of minor pressure points on the shoulders and irritation from the chin piece, when he neglected to shave.

#### *Asymmetrical and Other Difficult Cases*

Patient's asymmetrical disabilities were accommodated in a number of cases. For example, *patient 3* had muscle weakness on the right side because of a CVA. This, combined with narcolepsy, resulted in right lateral flexion. To compensate, a slightly longer lateral tube on the right side and a wider chin piece with upturned ends were used. *Patient 17*, a 4.5-year-old child with JRA, also had significant right lateral flexion (see Figure 1). This problem was overcome by the use of differing lengths of lateral tubes. Figure 8 depicts a marked improvement in posture, which was considered important in the patient's learning and development.

The most severe case encountered was *patient 12*, a 63-year-old female with severe RA (see Figure

**Figure 5**  
Lateral view of a hard-to-fit rheumatoid arthritis patient



5). The position shown of her neck and head was maintained when she sat independently; a collar was prescribed for pain relief. Attempts were made to fit her with plastazote and soft collars; however, these failed because of the lack of anterior space and the tenderness of the posterior occiput and neck. Extra-long posterior tubes were used to bridge over the tender areas. Although this collar was classified as only a partial success, it did provide pain relief caused by the jerkiness of her electric wheelchair.

#### *Additional Cases*

Subsequent to this study, 60 patients have been fitted with the collar to aid a variety of disabilities. An example of a severe asymmetrical case is shown in Figure 6. This woman had osteoarthritis, with a fixed elevation of the shoulder. The collar was able to accommodate this asymmetry, support

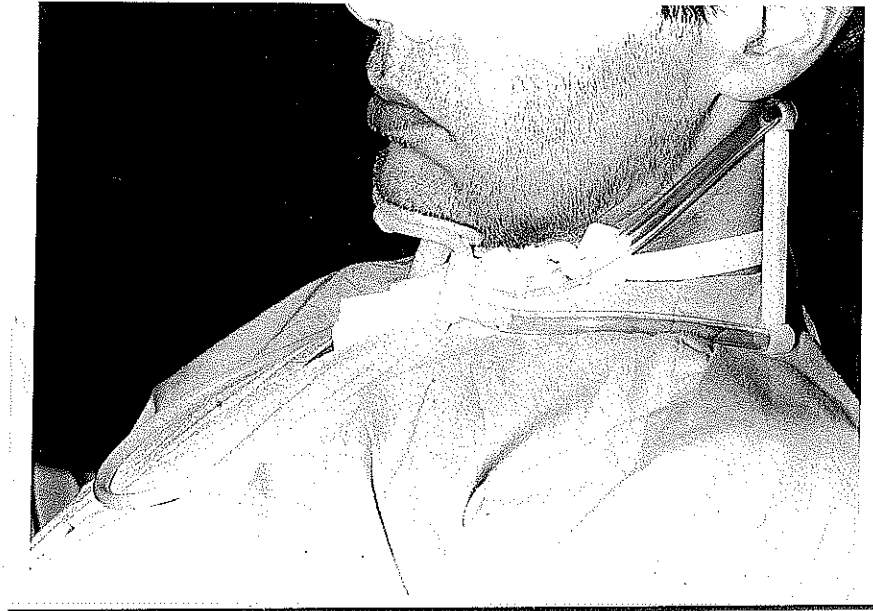**Figure 6**  
Patient with an asymmetrical disability



against flexion of the cervical spine, and provide pain relief.

An example of a patient with marked flexion contracture be-

**Figure 7**  
Patient with limited space anteriorly



cause of metastases of the cervical spine is shown in Figure 7. This patient's tracheal tube was occluded because of his posture and he required support to prevent increased flexion. The collar accommodated this posture and still provided access to the tracheal tube for suctioning.

Collar-fitting workshops for various occupational therapy departments were held around the province, and over 200 collar kits were distributed.

### Discussion

The objectives of the clinical trial of the collar have been met. The new collar has gained ready acceptance by patients and therapists, and it is now being specifically prescribed by physicians for cervical support. So far, we have been able to fit the collar on all patients.

The cosmetic considerations of collar wear are taken care of because the collar can be partially

hidden by clothing and hair. The front-fastening feature of the collar allows most patients with multijoint problems to apply the collar to themselves. Patients relay that this collar's coolness and increased support are the major advantages over the other types used in arthritis management.

The collar is primarily used in the management of RA and OA cervical spine instability, where it relieves soft tissue strain due to ligamentous laxity and protects against excessive movement of the damaged atlanto-axial joint.

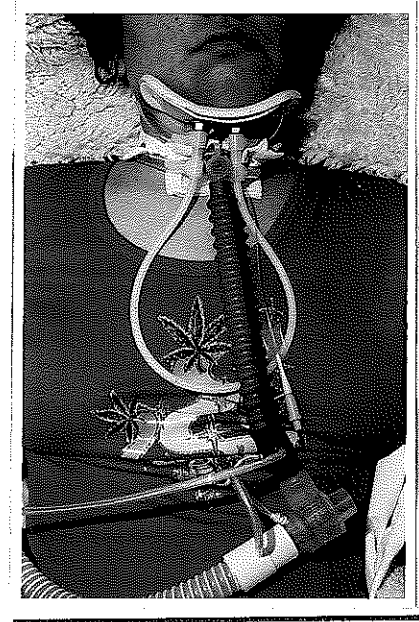
### Additional Areas of Application

The advantages to and the success of the collar encourage the application of the collar in other areas of disability. For example, *patient 2's* extensive use of the collar indicates that a snug fit can be tolerated for a long period of time and that the collar is supportive enough to be used for certain acute

spinal cord injuries. Use of the collar in emergency care (e.g., whiplash injuries) is also being considered. The whiplash case in this study (*patient 5*) was the only one who required an occipital pad to distribute the pressure of the collar evenly over the tender occiput.

Long-term protection and posture control for high-level spinal cord injured is also a potential area of application. For example, the patient in Figure 8 had a conventional four-poster brace that was difficult and inconsistent to apply when she was supine. An extra-wide chin piece was fabricated for increased stability. Further, the collar accommodates a tracheal respirator tube and was easy to apply. This patient was then transferred to an extended-care facility. An 8-year-old C<sub>1</sub> quadriplegic with a tracheal respirator tube has also been provided with the collar for use in bed/wheelchair transfers and for support during transportation.

**Figure 8**  
Use of the collar with a tracheal tube



Another potential area of application for the collar is in posture control in other cases of neurological impairment. Several patients having ALS, cerebral palsy, multiple sclerosis, or head injuries with the resulting flaccid neck musculature have been fitted with the new collar. Patients with these types of disabilities often need more head control than that which is provided by the standard collar; thus, modifications such as cupped chin pieces or lateral resists have been used.

Extension resists were provided in the following two cases: one patient who's neurological impairment required accurate and stable support against extension and one cerebral palsy patient with generalized head instability. The latter patient also required lateral resists of pvc tubing, which extended from the lateral and posterior tubes. The versatility of design indicates that cervico-thoracic orthoses is possible by extension of the structure using additional components.

## Conclusion

We have developed a cervical collar that provides improved comfort, cosmesis, and better support than that of existing cervical collars. This new collar was developed primarily for use on patients with arthritis and is designed to relieve the pain and/or neurological symptoms common to rheumatoid or osteo-arthritis of the cervical spine. It is also recommended for patients without symptoms where ligamentous laxity secondary to RA presents a danger of traumatic injury to the cervical spine. The collar has been readily accepted by patients, occupational therapists, and prescribing physicians.

Good results in diverse areas of application indicate that the orthosis is suitable for fabrication and fitting by either occupational therapists or orthotists. This collar enables occupational therapists to provide patients with cervical spine support more effectively. However, the management of difficult cases, such as treatment of acute spinal cord injury, where extensive

experience in orthotics may be required, calls for an orthotist.

This collar is an example of a new family of Tubular Orthoses that can be easily assembled and adjusted and that have significant functional advantages over conventional orthoses. Current plans for the collar include determination of the amount of cervical spine immobilization offered, via radiological studies, and extension of clinical trials to other disabilities, such as multiple sclerosis.

## REFERENCES

1. Johnson RM, Hart DL, Simmons EF, Ramsby GR, Southwick WO: Cervical orthoses. A study comparing their effectiveness in restricting cervical motion in normal subjects. *J Bone Joint Surg* 59:332-339, 1977
2. Johnson RM, Owen JR, Hart DL, Calahan RA: Cervical orthoses. A guide to their selection and use. *Clin Orthop* 154:34-45, 1981
3. Stauffer ES: Orthotics for spinal injuries. *Clin Orthop* 102:93-99, 1974
4. Hannah RE, Foort J, Cooper DG: Tubular orthoses. *Prosthetics and Orthotics International* 7:157-164, 1983

Note: The Canadian collar is available from G. A. Remington Ltd., 4747 Willowdale Place, Burnaby, British Columbia V5G 4B5 Canada.